

Hemoptysis: Diagnosis and Management

JACOB L. BIDWELL, M.D. and ROBERT W. PACHNER, M.D.

University of Wisconsin Medical School, Milwaukee, Wisconsin

Hemoptysis is the spitting of blood that originated in the lungs or bronchial tubes. The patient's history should help determine the amount of blood and differentiate between hemoptysis, pseudohemoptysis, and hematemesis. A focused physical examination can lead to the diagnosis in most cases. In children, lower respiratory tract infection and foreign body aspiration are common causes. In adults, bronchitis, bronchogenic carcinoma, and pneumonia are the major causes. Chest radiographs often aid in diagnosis and assist in using two complementary diagnostic procedures, fiberoptic bronchoscopy and high-resolution computed tomography, which are useful in difficult cases and when malignancy is suspected. The goals of management are threefold: bleeding cessation, aspiration prevention, and treatment of the underlying cause. Mild hemoptysis often is caused by an infection that can be managed on an outpatient basis with close monitoring. If hemoptysis persists, consulting with a pulmonologist should be considered. Patients with risk factors for malignancy or recurrent hemoptysis also require further evaluation with fiberoptic bronchoscopy or high-resolution computed tomography. In up to 34 percent of patients, no cause of hemoptysis can be found. (Am Fam Physician 2005;72:1253-60. Copyright © 2005 American Academy of Family Physicians.)

Hemoptysis is defined as the spitting of blood derived from the lungs or bronchial tubes as a result of pulmonary or bronchial hemorrhage.¹ Hemoptysis is classified as nonmassive or massive based on the volume of blood loss; however, there are no uniform definitions for these categories.² In this article, hemoptysis is considered nonmassive if blood loss is less than 200 mL per day.³ The lungs receive blood from the pulmonary and bronchial arterial systems.⁴ The low-pressure pulmonary system tends to produce small-volume hemoptysis, whereas bleeding from the bronchial system, which is at systemic pressure, tends to be profuse.⁴ Blood loss volume is more useful in directing management than in reaching a diagnosis.

After confirming the presence of blood, an initial task is differentiating between hemoptysis, pseudohemoptysis (i.e., the spitting of blood that does not come from the lungs or bronchial tubes), and hematemesis (i.e., the vomiting of blood).

Causes of Hemoptysis

In the primary care setting, the most common causes of hemoptysis are acute and chronic bronchitis, pneumonia, tuberculosis, and lung cancer. The differential diagnosis and underlying etiologies are listed in *Table 1*.⁵

INFECTION

Infection is the most common cause of hemoptysis, accounting for 60 to 70 percent of cases.⁵ Infection causes superficial mucosal inflammation and edema that can lead to the rupture of the superficial blood vessels. In a retrospective study⁶ of inpatient and outpatient hemoptysis in the United States, bronchitis caused 26 percent of cases, pneumonia caused 10 percent, and tuberculosis accounted for 8 percent. Invasive bacteria (e.g., *Staphylococcus aureus*, *Pseudomonas aeruginosa*) or fungi (e.g., *Aspergillus* species) are the most common infectious causes of hemoptysis. Viruses such as influenza also may cause severe hemoptysis.⁷ Human immunodeficiency virus (HIV) infection predisposes patients to several conditions that may produce hemoptysis, including pulmonary Kaposi's sarcoma.⁸

CANCER

Primary lung cancers account for 23 percent of cases of hemoptysis in the United States.⁶ Bronchogenic carcinoma is a common lung cancer responsible for hemoptysis in 5 to 44 percent of all cases.^{9,10} Bleeding from malignant or benign tumors can be secondary to superficial mucosal invasion, erosion into blood vessels, or highly vascular lesions. Breast, renal, and colon cancers have a predilection for lung metastasis; however,

The first step in making a diagnosis is to differentiate hemoptysis from pseudohemoptysis or hematemesis.

SORT: KEY RECOMMENDATIONS FOR PRACTICE

<i>Clinical recommendation</i>	<i>Evidence rating</i>	<i>Reference</i>
Patients with evidence of parenchymal disease should have high-resolution CT, and those with a mass should be considered for bronchoscopy.	C	5
Patients with normal chest radiograph, no risk factors for cancer, and findings not suggestive for infection should be considered for bronchoscopy or high-resolution CT.	C	5
After extensive initial investigation, closely follow smokers older than 40 years who have unexplained hemoptysis.	C	6, 12, 13

CT=computed tomography.

A = consistent, good-quality, patient-oriented evidence; B = inconsistent or limited-quality, patient-oriented evidence; C = consensus, disease-oriented evidence, usual practice, expert opinion, or case series. For information about the SORT evidence rating system, see page 1154 or <http://www.aafp.org/afpsort.xml>.

metastatic lung carcinoma rarely results in bleeding.⁶ Obstructive lesions may cause a secondary infection, resulting in hemoptysis.

PULMONARY VENOUS HYPERTENSION

Cardiovascular conditions that result in pulmonary venous hypertension can cause cardiac hemoptysis. The most common of these is left ventricular systolic heart failure. Other cardiovascular causes include severe mitral stenosis and pulmonary embolism. Although hemoptysis is a recognized pulmonary embolism symptom, pulmonary embolism is an uncommon cause of hemoptysis. For example, in a patient without underlying cardiopulmonary disease, the positive and negative likelihood ratios for hemoptysis in pulmonary embolism are 1.6 and

0.95, respectively. Therefore, the presence or absence of hemoptysis alone has no significant effect on the likelihood of pulmonary embolism.¹¹

IDIOPATHY

Idiopathic hemoptysis is a diagnosis of exclusion. In 7 to 34 percent of patients with hemoptysis, no identifiable cause can be found after careful evaluation.^{6,12,13} Prognosis for idiopathic hemoptysis usually is good, and the majority of patients have resolution of bleeding within six months of evaluation.¹⁴ However, results from one study¹³ found an increasing incidence of lung cancer in smokers older than 40 years with idiopathic hemoptysis, and suggested that these patients may warrant close monitoring.¹³

TABLE 1
Differential Diagnosis of Hemoptysis

Source other than the lower respiratory tract	Pulmonary parenchymal source	Primary vascular source
Upper airway (nasopharyngeal) bleeding	Lung abscess	Arteriovenous malformation
Gastrointestinal bleeding	Pneumonia	Pulmonary embolism
Tracheobronchial source	Tuberculosis	Elevated pulmonary venous pressure (especially mitral stenosis)
Neoplasm (bronchogenic carcinoma, endobronchial metastatic tumor, Kaposi's sarcoma, bronchial carcinoid)	Mycetoma ("fungus ball")	Pulmonary artery rupture secondary to balloon-tip pulmonary artery catheter manipulation
Bronchitis (acute or chronic)	Goodpasture's syndrome	Miscellaneous and rare causes
Bronchiectasis	Idiopathic pulmonary hemosiderosis	Pulmonary endometriosis
Broncholithiasis	Wegener's granulomatosis	Systemic coagulopathy or use of anticoagulants or thrombolytic agents
Airway trauma	Lupus pneumonitis	
Foreign body	Long contusion	

Adapted with permission from Weinberger SE. *Principles of pulmonary medicine*. 3d ed. Philadelphia: Saunders, 1998.

TABLE 2
Differentiating Features of Hemoptysis and Hematemesis

<i>Hemoptysis</i>	<i>Hematemesis</i>
History	
Absence of nausea and vomiting	Presence of nausea and vomiting
Lung disease	Gastric or hepatic disease
Asphyxia possible	Asphyxia unusual
Sputum examination	
Frothy	Rarely frothy
Liquid or clotted appearance	Coffee ground appearance
Bright red or pink	Brown to black
Laboratory	
Alkaline pH	Acidic pH
Mixed with macrophages and neutrophils	Mixed with food particles

Information from references 4, 17, and 18.

HEMOPTYSIS IN CHILDREN

The major cause of hemoptysis in children is lower respiratory tract infection. The second most common cause is foreign body

aspiration, with most cases occurring in children younger than four years. Another important cause is bronchiectasis, which often is secondary to cystic fibrosis. Primary pulmonary tuberculosis is a rare cause estimated to occur in less than 1 percent of cases.¹⁵ Although uncommon, trauma is another possible cause. Blunt-force trauma may result in hemoptysis secondary to pulmonary contusion and hemorrhage. Bleeding caused by suffocation, deliberate or accidental, also should be considered.¹⁶

Patient History

Historic clues are useful for differentiating hemoptysis from hematemesis (Table 2^{4,17,18}). Patient history also can help identify the anatomic site of bleeding, differentiate between hemoptysis and pseudohemoptysis, and narrow the differential diagnosis (Table 3^{4,5,17,18}). Factors such as age,

TABLE 3
Diagnostic Clues in Hemoptysis: Physical History

<i>Clinical clues</i>	<i>Suggested diagnosis*</i>
Anticoagulant use	Medication effect, coagulation disorder
Association with menses	Catamenial hemoptysis
Dyspnea on exertion, fatigue, orthopnea, paroxysmal nocturnal dyspnea, frothy pink sputum	Congestive heart failure, left ventricular dysfunction, mitral valve stenosis
Fever, productive cough	Upper respiratory infection, acute sinusitis, acute bronchitis, pneumonia, lung abscess
History of breast, colon, or renal cancers	Endobronchial metastatic disease of lungs
History of chronic lung disease, recurrent lower respiratory track infection, cough with copious purulent sputum	Bronchiectasis, lung abscess
HIV, immunosuppression	Neoplasia, tuberculosis, Kaposi's sarcoma
Nausea, vomiting, melena, alcoholism, chronic use of nonsteroidal anti-inflammatory drugs	Gastritis, gastric or peptic ulcer, esophageal varices
Pleuritic chest pain, calf tenderness	Pulmonary embolism or infarction
Tobacco use	Acute bronchitis, chronic bronchitis, lung cancer, pneumonia
Travel history	Tuberculosis, parasites (e.g., paragonimiasis, schistosomiasis, amebiasis, leptospirosis), biologic agents (e.g., plague, tularemia, T2 mycotoxin)
Weight loss	Emphysema, lung cancer, tuberculosis, bronchiectasis, lung abscess, HIV

HIV = human immunodeficiency virus.

**—Arranged from most to least common diagnosis for each clinical clue.*

Information from references 4, 5, 17, and 18.

Low-risk patients with normal chest radiographs can be treated on an outpatient basis with close monitoring and appropriate oral antibiotics, if medication is clinically indicated.

nutrition status, and comorbid conditions can assist in the diagnosis and management of hemoptysis.

Once true hemoptysis is suspected, the investigation should focus on the respiratory system. Blood from the lower bronchial tree typically induces cough, whereas a history of epistaxis or expectorating without cough would be consistent with an upper respiratory source but does not exclude a lower tract site.

Bleeding is difficult to quantify clinically. Patients may find it difficult to discern whether they are throwing up, coughing, or spitting out bloody material. The amount of blood loss usually is overestimated by patients and physicians, but an attempt to determine the volume and rate of blood loss should be made. Methods of determination include observing as the patient coughs and the use of a graduated container. Blood-streaked sputum deserves the same diagnostic consideration as blood alone. The amount or frequency of bleeding does not correlate with the diagnosis or incidence of cancer.

It is helpful to determine whether there have been previous episodes of hemoptysis and what diagnostic assessments have been done. Mild hemoptysis recurring sporadically over a few years is common in smokers who have chronic bronchitis punctuated with superimposed acute bronchitis. Because smoking is an important risk factor,

these patients are at higher risk for lung cancer.¹⁹ Chronic obstructive pulmonary disease also is an independent risk factor for hemoptysis.

Environmental exposure to asbestos, arsenic, chromium, nickel, and certain ethers increases risk for hemoptysis. Bronchial adenomas, although malignant, are slow growing and may present with occasional bleeding over many years. Malignancy in general, especially adenocarcinomas, can induce a hypercoagulable state, thereby increasing the risk for a pulmonary embolism. A history of chronic, purulent sputum production and frequent pneumonias, including tuberculosis, may represent bronchiectasis. Association of hemoptysis with menses (i.e., catamenial hemoptysis) may represent intrathoracic endometriosis.²⁰

A travel history may be helpful. Tuberculosis is endemic in many parts of the world, and parasitic etiologies should be considered.^{21,22} In regions where drinking from springs is common, there are case reports of hemoptysis caused by leeches attaching to the upper respiratory tract mucosa.²³ Also, biologic weapons such as plague may cause hemoptysis.^{17,24}

Physical Examination

Historic clues often will narrow the differential diagnosis and help focus the physical examination (*Table 4^{4,5,17}*). Examining the expectoration may help localize the source of bleeding.^{4,17,18} The physician should record vital signs, including pulse oximetry levels, to document fever, tachycardia, tachypnea, weight changes, and hypoxia. Constitutional signs such as cachexia and level of patient distress also should be noted. The skin and mucous membranes should be inspected for cyanosis, pallor, ecchymoses, telangiectasia, gingivitis, or evidence of bleeding from the oral or nasal mucosa.

The examination for lymph node enlargement should include the neck, supraclavicular region, and axillae. The cardiovascular examination includes an evaluation for jugular venous distention, abnormal heart sounds, and edema. The physician should check the chest and lungs for signs of

The Authors

JACOB L. BIDWELL, M.D., is a University of Wisconsin assistant professor of Family Medicine at St. Luke's Medical Center in Milwaukee and serves as medical director of Walker's Point Community Clinic. Dr. Bidwell received his undergraduate and medical degrees from the University of Wisconsin, Madison. He completed his family medicine residency at St. Luke's Medical Center.

ROBERT W. PACHNER, M.D., is clinical assistant professor with the University of Wisconsin Department of Family Medicine in Milwaukee. Dr. Pachner graduated from the Medical College of Wisconsin and completed a family practice residency at St. Luke's Medical Center.

Address correspondence to Jacob L. Bidwell, M.D., University of Wisconsin Medical School, 2801 W. Kinnickinnie River Parkway, Suite 175, Milwaukee, WI 53215 (e-mail: jbidwell@fammed.wisc.edu). Reprints are not available from the authors.

consolidation, wheezing, rales, and trauma. The abdominal examination should focus on signs of hepatic congestion or masses, with an inspection of the extremities for signs of edema, cyanosis, or clubbing.^{4,25}

Diagnostic Evaluation

Figure 1⁵ presents an algorithm for the evaluation of nonmassive hemoptysis. After a careful history and examination, a chest radiograph should be obtained (Table 5^{4,17}). If a diagnosis remains unclear, further imaging with chest computed tomography (CT) or direct visualization with bronchoscopy often is indicated. In high-risk patients with a normal chest radiograph, fiberoptic bronchoscopy should be considered to rule out malignancy. Risk factors that increase the likelihood of finding lung cancer on

bronchoscopy include male sex, older than 40 years, a smoking history of more than 40 pack-years, and duration of hemoptysis for more than one week.²⁶

Fiberoptic bronchoscopy is preferred if neoplasia is suspected; it is diagnostic for central endobronchial disease and allows for direct visualization of the bleeding site. It also permits tissue biopsy, bronchial lavage, or brushings for pathologic diagnosis. Fiberoptic bronchoscopy also can provide direct therapy in cases of continued bleeding. Rigid bronchoscopy is the preferred tool for cases of massive bleeding because of its greater suctioning and airway maintenance capabilities.

High-resolution CT has become increasingly useful in the initial evaluation of hemoptysis and is preferred if parenchymal

TABLE 4
Diagnostic Clues in Hemoptysis: Physical Examination

Clinical clues	Suggested diagnosis*
Cachexia, clubbing, voice hoarseness, Cushing's syndrome, hyperpigmentation, Horner's syndrome	Bronchogenic carcinoma, small cell lung cancer, other primary lung cancers
Clubbing	Primary lung cancer, bronchiectasis, lung abscess, severe chronic lung disease, secondary lung metastases
Dullness to percussion, fever, unilateral rales	Pneumonia
Facial tenderness, fever, mucopurulent nasal discharge, postnasal drainage	Acute upper respiratory infection, acute sinusitis
Fever, tachypnea, hypoxia, hypertrophied accessory respiratory muscles, barrel chest, intercostal retractions, pursed lip breathing, rhonchi, wheezing, tympani to percussion, distant heart sounds	Acute exacerbation of chronic bronchitis, primary lung cancer, pneumonia
Gingival thickening, mulberry gingivitis, saddle nose, nasal septum perforation	Wegener's granulomatosis
Heart murmur, pectus excavatum	Mitral valve stenosis
Lymph node enlargement, cachexia, violaceous tumors on skin	Kaposi's sarcoma secondary to human immunodeficiency virus infection
Orofacial and mucous membrane telangiectasia, epistaxis	Osler-Weber-Rendu disease
Tachycardia, tachypnea, hypoxia, jugulovenous distention, S3 gallop, decreased lung sounds, bilateral rales, dullness to percussion in lower lung fields	Congestive heart failure caused by left ventricular dysfunction or severe mitral valve stenosis
Tachypnea, tachycardia, dyspnea, fixed split S2, pleural friction rub, unilateral leg pain and edema	Pulmonary thromboembolic disease
Tympani to percussion over lung apices, cachexia	Tuberculosis

*—Arranged from most to least common diagnosis for each clinical clue.

Information from references 4, 5, and 17.

Diagnosing Nonmassive Hemoptysis

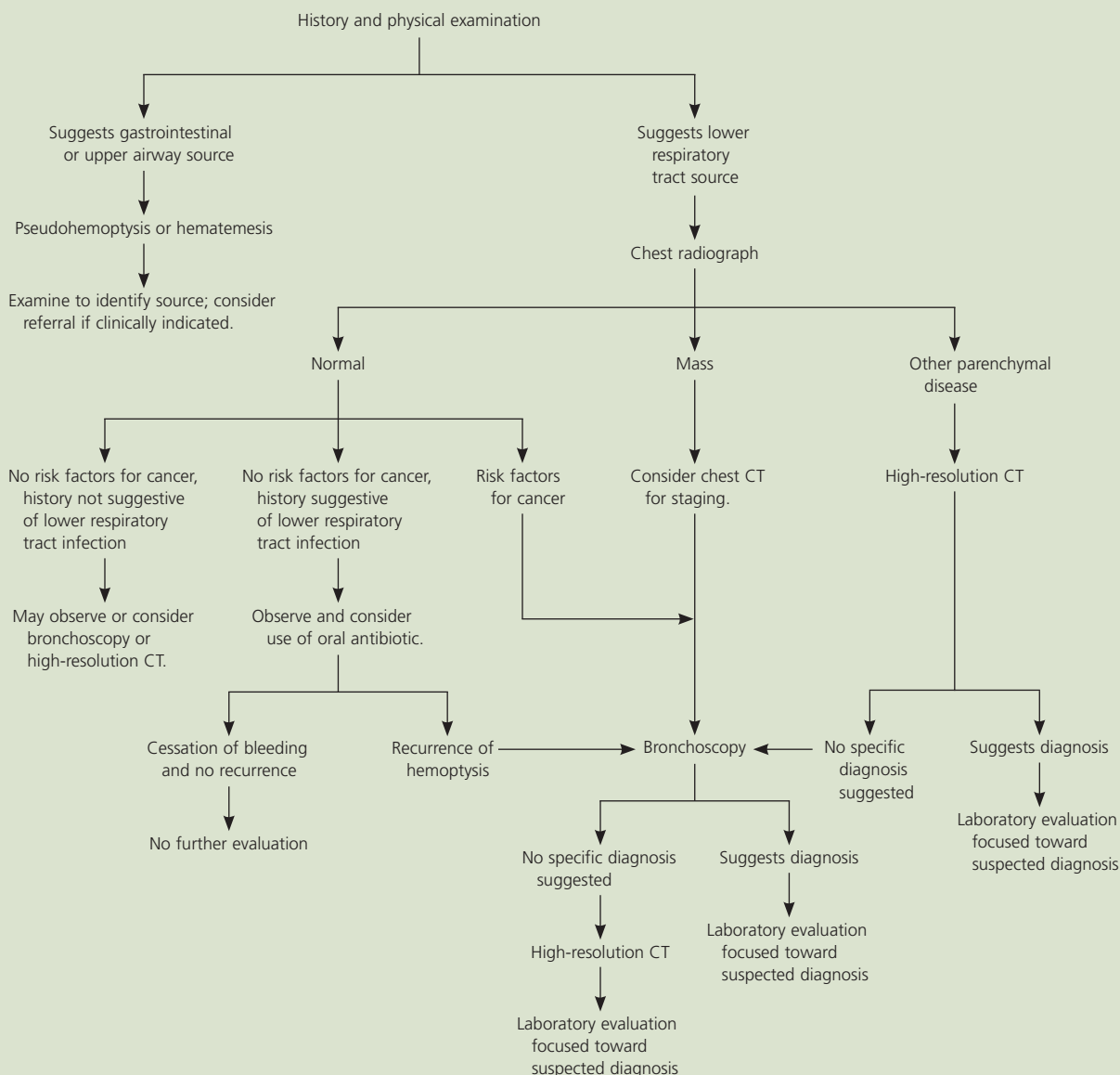


Figure 1. Algorithm for diagnosing nonmassive hemoptysis. (CT = computed tomography.)

Adapted with permission from Harrison TR, Braunwald E. Cough and hemoptysis. In: Harrison's Principles of internal medicine. 15th ed. New York: McGraw-Hill, 2001:208.

disease is suspected. Its complementary use with bronchoscopy gives a greater positive yield of pathology^{12,27,28} and is useful for excluding malignancy in high-risk patients.²⁹ Its role in hemoptysis continues to evolve, and further studies are needed to evaluate its effect on patient management and outcome. Patients with recurrent or unexplained hemoptysis may need additional laboratory evaluation to establish a diagnosis (Table 6^{5,17}).

Management

NONMASSIVE HEMOPTYSIS

The overall goals of management of the patient with hemoptysis are threefold: bleeding cessation, aspiration prevention, and treatment of the underlying cause. As with any potentially serious condition, evaluation of the "ABCs" (i.e., airway, breathing, and circulation) is the initial step.

The most common presentation is acute, mild hemoptysis caused by bronchitis.

TABLE 5
Diagnostic Clues in Hemoptysis: Chest Radiograph

<i>Chest radiograph finding</i>	<i>Suggested diagnosis*</i>
Cardiomegaly, increased pulmonary vascular distribution	Chronic heart failure, mitral valve stenosis
Cavitary lesions	Lung abscess, tuberculosis, necrotizing carcinoma
Diffuse alveolar infiltrates	Chronic heart failure, pulmonary edema, aspiration, toxic injury
Hilar adenopathy or mass	Carcinoma, metastatic disease, infectious process, sarcoid
Hyperinflation	Chronic obstructive pulmonary disease
Lobar or segmental infiltrates	Pneumonia, thromboembolism, obstructing carcinoma
Mass lesion, nodules, granulomas	Carcinoma, metastatic disease, Wegener's granulomatosis, septic embolism, vasculitides
Normal or no change from baseline	Bronchitis, upper respiratory infection, sinusitis, pulmonary embolism
Patchy alveolar infiltrates (multiple bleeding sites)	Bleeding disorders, idiopathic pulmonary hemosiderosis, Goodpasture's syndrome

*—Arranged from most to least common diagnosis for each clinical clue.

Information from references 4 and 17.

TABLE 6
Diagnostic Clues in Hemoptysis: Laboratory Tests

<i>Test</i>	<i>Diagnostic findings</i>
White blood cell count and differential	Elevated cell count and differential shifts may be present in upper and lower respiratory tract infections
Hemoglobin, hematocrit	Decreased in anemia
Platelet count	Decreased in thrombocytopenia
Prothrombin time, International Normalized Ratio, partial thromboplastin time	Increased in anticoagulant use, disorders of coagulation
Arterial blood gases	Hypoxia, hypercarbia
D-dimer	Elevated in pulmonary embolism
Sputum Gram stain, culture, acid-fast bacillus smear and culture	Pneumonia, lung abscess, tuberculosis, mycobacterial infections
Sputum cytology	Neoplasm
Purified protein derivative skin test	Positive increases risk for tuberculosis
Human immunodeficiency virus test	Positive increases risk for tuberculosis, Kaposi's sarcoma
Erythrocyte sedimentation rate	Elevated in infection, autoimmune disorders (e.g., Wegener's syndrome, systemic lupus erythematosus, sarcoid, Goodpasture's syndrome), may be elevated in neoplasia

Information from references 5 and 17.

Low-risk patients with normal chest radiographs can be treated on an outpatient basis with close monitoring and appropriate oral antibiotics, if clinically indicated. If hemoptysis persists or remains unexplained, an outpatient evaluation by a pulmonologist should be considered.

An abnormal mass on a chest radiograph

warrants an outpatient bronchoscopic examination. For patients with a normal chest radiograph and risk factors for lung cancer or recurrent hemoptysis, outpatient fiberoptic bronchoscopy also is indicated to rule out neoplasm. High-resolution CT is indicated when clinical suspicion for malignancy exists and sputum and bronchoscopy do not yield

any pathology. High-resolution CT also is indicated when chest radiography reveals peripheral or other parenchymal disease.

MASSIVE HEMOPTYSIS

The mortality rate from massive hemoptysis depends on the bleeding rate and etiology. Hemoptysis greater than 1,000 mL per 24 hours in the presence of malignancy carries a mortality rate of 80 percent³⁰; therefore, massive hemoptysis warrants a more aggressive, expedient approach. These patients require intensive care and early consultation with a pulmonologist. In cases of massive or life-threatening hemoptysis, diagnosis and therapy must occur simultaneously. Airway maintenance is vital because the primary mechanism of death is asphyxiation, not exsanguination. Supplemental oxygen and fluid resuscitation are essential. Assistance by a cardiothoracic surgeon should be considered because emergency surgical intervention may be needed.

Author disclosure: Nothing to disclose.

REFERENCES

1. Stedman TL. Stedman's Medical dictionary. 27th ed. Philadelphia: Lipincott Williams & Wilkins, 2000.
2. Thompson AB, Teschler H, Rennard SI. Pathogenesis, evaluation, and therapy for massive hemoptysis. *Clin Chest Med* 1992;13:69-82.
3. Knott-Craig CJ, Oosthuizen JG, Rossouw G, Joubert JR, Barnard PM. Management and prognosis of massive hemoptysis. Recent experience with 120 patients. *J Thorac Cardiovasc Surg* 1993;105:394-7.
4. Cahill BC, Ingbar DH. Massive hemoptysis. Assessment and management. *Clin Chest Med* 1994;15:147-67.
5. Harrison TR, Braunwald E. Hemoptysis. In: Harrison's Principles of internal medicine. 15th ed. New York: McGraw-Hill, 2001:203-6.
6. Reisz G, Stevens D, Boutwell C, Nair V. The causes of hemoptysis revisited. A review of the etiologies of hemoptysis between 1986 and 1995. *Mo Med* 1997;94:633-5.
7. Bond D, Vyas H. Viral pneumonia and hemoptysis. *Crit Care Med* 2001;29:2040-1.
8. Nelson JE, Forman M. Hemoptysis in HIV-infected patients. *Chest* 1996;110:737-43.
9. Santiago S, Tobias J, Williams AJ. A reappraisal of the causes of hemoptysis. *Arch Intern Med* 1991;151:2449-51.
10. Hirshberg B, Biran I, Glazer M, Kramer MR. Hemoptysis: etiology, evaluation, and outcome in a tertiary referral hospital. *Chest* 1997;112:440-4.
11. Anish EJ, Mayewski RJ. Pulmonary embolism. In: Black ER, ed. Diagnostic strategies for common medical problems. Philadelphia: American College of Physicians, 1999:325-37.
12. Set PA, Flower CD, Smith IE, Chan AP, Twentyman OP, Shneerson JM. Hemoptysis: comparative study of the role of CT and fiberoptic bronchoscopy. *Radiology* 1993;189:677-80.
13. Herth F, Ernst A, Becker HD. Long-term outcome and lung cancer incidence in patients with hemoptysis of unknown origin. *Chest* 2001;120:1592-4.
14. Adelman M, Haponik EF, Bleecker ER, Britt EJ. Cryptogenic hemoptysis. Clinical features, bronchoscopic findings, and natural history in 67 patients. *Ann Intern Med* 1985;102:829-34.
15. Pianosi P, al-sadoon H. Hemoptysis in children. *Pediatr Rev* 1996;17:344-8.
16. Godfrey S. Hemoptysis in children. *Pediatr Pulmonol Suppl* 2004;26:177-9.
17. Corder R. Hemoptysis. *Emerg Med Clin North Am* 2003;21:421-35.
18. Camacho JR, Prakash UB. 46-year-old man with chronic hemoptysis. *Mayo Clin Proc* 1995;70:83-6.
19. Humphrey LL, Teutsch S, Johnson M; U.S. Preventive Services Task Force. Lung cancer screening with sputum cytologic examination, chest radiography, and computed tomography. *Ann Intern Med* 2004;140:740-53.
20. Weber F. Catamenial hemoptysis. *Ann Thorac Surg* 2001;72:1750-1.
21. Soni PN, Reddy I, Rauff S. Pneumonia and severe haemoptysis. *Lancet* 1998;352:198.
22. Procop GW, Marty AM, Scheck DN, Mease DR, Maw GM. North American paragonimiasis. A case report. *Acta Cytol* 2000;44:75-80.
23. Kaygusuz I, Yalcin S, Keles E. Leeches in the larynx. *Eur Arch Otorhinolaryngol* 2001;258:455-7.
24. Inglesby TV, Dennis DT, Henderson DA, Bartlett JG, Ascher MS, Eitzen E, et al. Plague as a biological weapon: medical and public health management. *JAMA* 2000;283:2281-90.
25. Gregory RK, Chang J, Singh R, Powles TJ. Clubbing, arthralgia and haemoptysis in a patient with metastatic carcinoma of the breast. *Ann Oncol* 1996;7:756-7.
26. O'Neil KM, Lazarus AA. Hemoptysis. Indications for bronchoscopy. *Arch Intern Med* 1991;151:171-4.
27. McGuinness G, Beacher JR, Harkin TJ, Garay SM, Rom WN, Naidich DP. Hemoptysis: prospective high-resolution CT/bronchoscopic correlation. *Chest* 1994;105:1155-62.
28. Tasker AD, Flower CD. Imaging the airways. Hemoptysis, bronchiectasis, and small airways disease. *Clin Chest Med* 1999;20:761-73,viii.
29. Colice GL. Detecting lung cancer as a cause of hemoptysis in patients with a normal chest radiograph: bronchoscopy vs CT. *Chest* 1997;111:877-84.
30. Jean-Baptiste E. Clinical assessment and management of massive hemoptysis. *Crit Care Med* 2000;28:1642-7.